

## Advances in Treating Macular Degeneration

Geeta Lalwani, MD  
Rocky Mountain Retina Associates  
303-963-9669



## Training

- Smith College- Massachusetts
  - Chemistry & Japanese
- MCP-Hahnemann- Philadelphia, PA
- Case Western Reserve- Cleveland, OH
- Bascom Palmer Eye Institute, Miami, FL
  - 2 year surgical fellowship in retina

## Bascom Palmer Eye Institute #1 Eye Institute 12 years in a row!

- Clinical professor of ophthalmology-  
vitreoretinal surgery
  - Areas of Research
    - Age related macular degeneration
    - Diabetes
      - Surgical Management
      - Diabetic Macular Edema
    - Spectral Domain OCT



## Disclosures

- Consulting Fees: Allergan, Alcon, B&L, Genentech, Novartis, Regeneron, DORC
- Ownership interests: Ocugen



## ROCKY MOUNTAIN RETINA ASSOCIATES

4430 Arapahoe Ave, Boulder, CO 80303  
702 W. Drake Ave, Ft Collins, CO 80526  
1330 Vivian Street, Longmont, CO 80501

## Outline

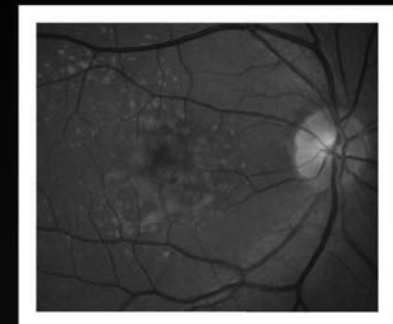
- Definitions
- Tools to assess and monitor intermediate to late disease
- Minimizing progression
- Current and emerging options for treatment
- Improving patient quality of life through vision loss aids and services

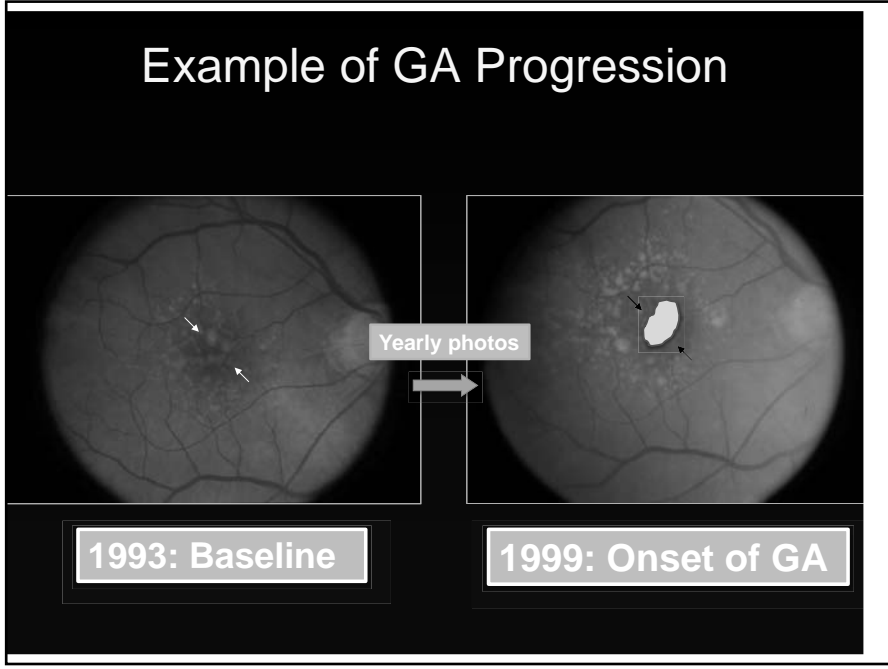
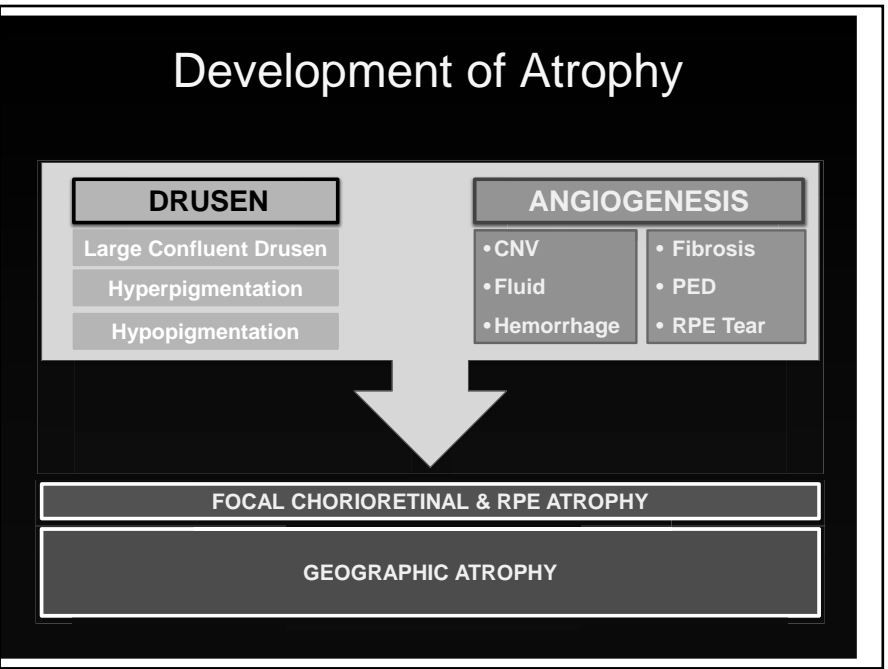
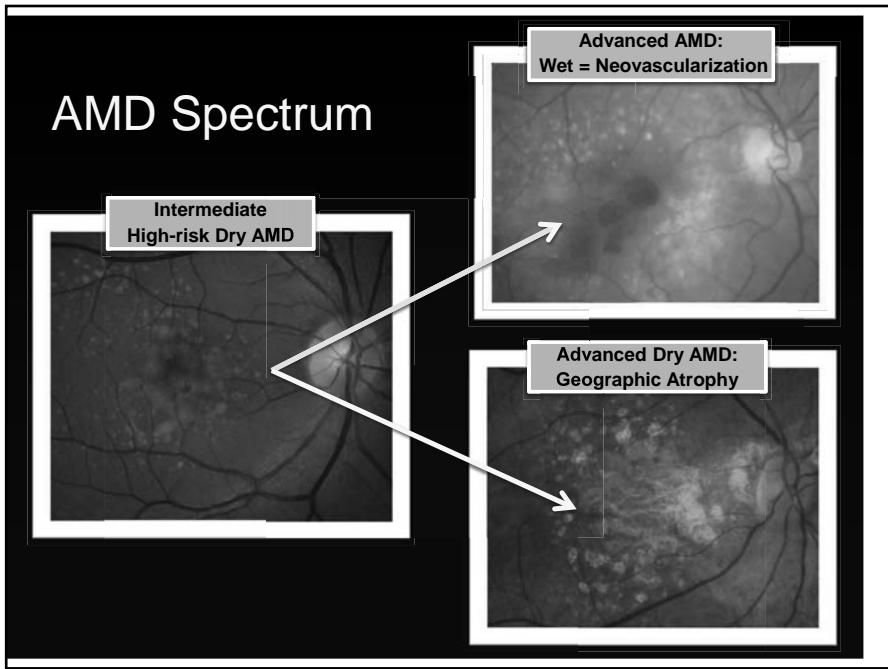
## Outline

- Definitions
- Tools to assess and monitor intermediate to late disease
- Minimizing progression
- Current and emerging options for treatment
- Improving patient quality of life through vision loss aids and services

## Early & Intermediate AMD


- Early AMD
  - Fine drusen, RPE mottling
- Intermediate AMD
  - Small, intermediate, or large sized drusen
  - Choriorretinal atrophy
  - RPE hyperplasia (“pigment”)



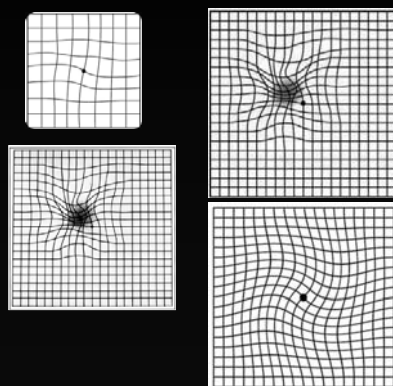


- ### Outline
- Definitions
  - Tools to assess and monitor intermediate to late disease
  - Minimizing progression
  - Current and emerging options for treatment
  - Improving patient quality of life through vision loss aids and services

## Metamorphopsia & Scotoma

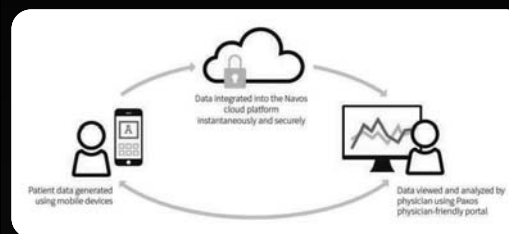


Normal



Abnormal

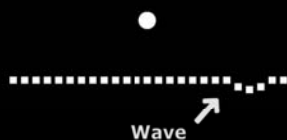
## Digisight: Paxos Checkup



## Home Monitoring for CNV



Mark the Wave



### Foresee Home monitoring System

- High risk dry AMD in both eyes
- Vision better than 20/60

## HOME Study Background

**1,520**  
participants

Randomized 1:1 to AMD monitoring device + standard care (device monitoring arm), or standard care alone to determine which arm improved the detection of the progression to CNV in dry AMD eyes

**44**  
Centers

Part of the National Eye Institute's (NEI) Age-related Eye Disease Study 2 (AREDS2) on nutritional supplements in the prevention of AMD.

## Defining CNV Events


Device Monitoring Arm:  
**51 CNV Events**

Changes in vision were detected by the AMD monitoring device using Preferential Hyperacuity Perimetry (PHP), causing an “alert” when significant changes were detected by the device, by symptoms or during office visits

Standard Care Arm:  
**31 CNV Events**

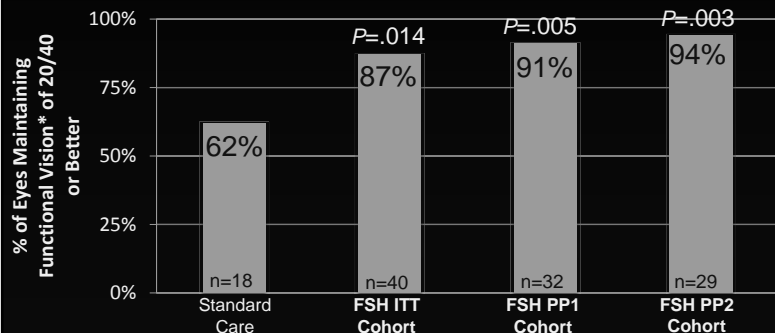
Changes in vision were detected by symptom realization by the participant or during office visits

## # of Letters of Lost



\* Excluded one eye with no VA data at the time of CNV Event

## Proportion of Patients 20/40 or Better



\* HOME Study used EDTRS chart to measure the number of letters. Snellen equivalent is presented here.

## Early Efficacy = Early End to the Study

- The Data Safety and Monitoring committee recommended study termination at the interim analysis of 80% of the target CNV events for the HOME Study, because the study demonstrated that *eyes that progressed to neovascular AMD, were identified with significantly better levels of visual acuity in the device monitoring arm compared to standard care alone.*

## Outline

- Definitions
- Tools to assess and monitor intermediate to late disease
- Minimizing progression
- Current and emerging options for treatment
- Improving patient quality of life through vision loss aids and services

## Aging and Malnutrition

- Of those over age 65 in community setting:
  - 5% to 10% are malnourished
  - 35% in long-term care facilities
  - 60% in hospitals

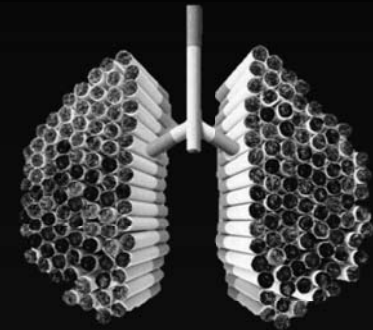


Hajjar R, et al. *The Internet Journal of Geriatrics and Gerontology*. 2003;1(1).

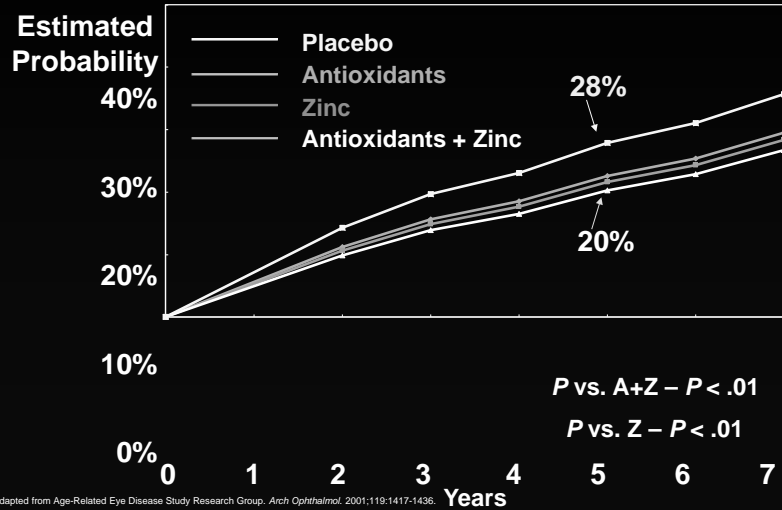
## Eating a Healthy Balanced Diet



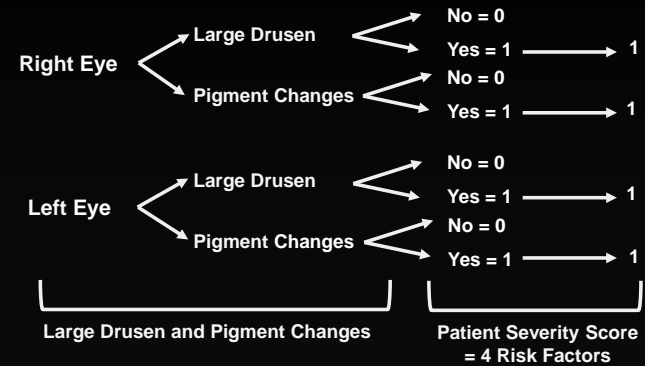
## Avoidance of Smoking



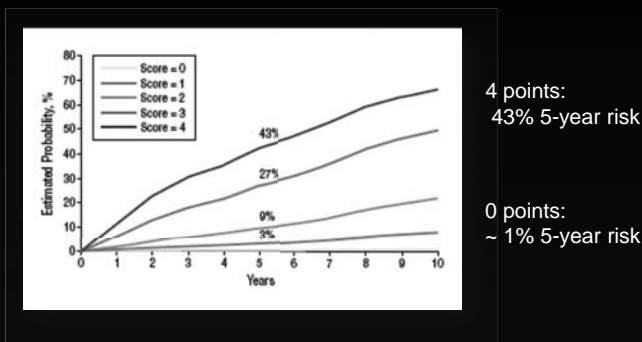
## Rate to Advanced AMD AMD Categories 3 and 4 by Treatment Group



## AREDS SIMPLIFIED SYSTEM SCORE OF 0 TO 4 POINTS



## Risk of Progression to Advanced AMD



## Micronutrient Supplementation



AREDS  
and  
AREDS2



## Age Related Eye Disease Study

### AREDS I

- Vitamin C (500 mg)
- Vitamin E (400 IU)
- Zinc (80 mg)
- Copper (2mg)
  
- Beta carotene (15 mg)

### AREDS II

- Vitamin C (500 mg)
- Vitamin E (400 IU)
- Zinc (80 mg)
- Copper (2mg)
  
- Lutein (10mg)
- Zeaxanthin (2mg)
- ? Omega 3

## AREDS2: Beta-Carotene?

- There was no apparent effect of beta-carotene elimination or lower-dose zinc on progression to advanced AMD.
- More lung cancers were noted in the beta-carotene vs no beta-carotene group (23 [2.0%] vs 11 [0.9%], nominal  $P=.04$ ), mostly in former smokers.

AREDS2 Research Group, et al. *JAMA*. 2013;309:2005-2015.

## AREDS 2 Bottom Line

- **Negative study**
- **Addition of omega-3 fatty acids not beneficial**
- **Use a lutein/zeaxanthin-containing preparation in place of beta-carotene OK**
  - **No need to have the “if you are a smoker ” discussion**

## Carotenoids Age-related Eye Disease Study (CAREDS)

- Adherence to a Mediterranean diet associated with lower prevalence of early AMD
  - Diet scored on intake of vegetables, fruit, legumes, alcohol and ratio of monounsaturated fats
  - Adjusted for demographic, behavioral, ocular and genetic factors



- High score associated with 26% reduced risk with progression to advanced AMD
  - Addition of supplements did not have an impact

B Merle et al. Adherence to the Mediterranean diet, genetic susceptibility and progression to advanced macular degeneration: a prospective cohort study. Am J Clin Nutr 2015;102:1196-206.

## Outline

- Definitions
- Tools to assess and monitor intermediate to late disease
- Minimizing progression
- Current and emerging options for treatment
- Improving patient quality of life through vision loss aids and services

## Treatments: Wet AMD

CURRENT & PAST	FUTURE
<ul style="list-style-type: none"> <li>• Micronutrients</li> <li>• Anti-VEGF Agents</li> <li>• Photodynamic Therapy</li> <li>• Thermal Laser</li> </ul>	<ul style="list-style-type: none"> <li>• Synergistic therapies</li> <li>• Longer-lasting molecules</li> <li>• Sustained release implants</li> <li>• Gene therapy</li> </ul>

## Anti VEGF Agents

- AVASTIN
  - First anti VEGF used publically (2005)
  - Originally developed for Colon CA treatment
  - Numerous head to head trials fro AMD (and other diseases) demonstrates equal efficacy and safety
- LUCENTIS
  - First FDA approved anti VEGF (2006)
  - Strong safety data
- EYLEA
  - Combined anti VEGF and anti PDGF
  - Non-inferior to Lucentis

## New anti VEGF- Brolucizumab

- Smaller molecule with better retinal penetration
- Perhaps longer duration therefore requiring fewer injections
- FDA approved- available 2019

## Injections for wet AMD

- Chronic treatment
- Will start as monthly treatments and slowly increase interval between treatments
- NO PAIN with the injections

## Current Treatments: Dry AMD

### Drusen

- Micronutrients

### Geographic Atrophy

- None

## Future Treatments: Dry AMD

### Drusen

- Micronutrients
- Complement Inhibitors

### Geographic Atrophy

- Complement Inhibitors
- Gene therapy
- Stem cell therapy

• *Dry is the new wet....*

## Complement Inhibitors in Clinical Trials

- Anti-C3 cyclic peptide
  - POT-4 (intravitreal)
  - APL-2 (intravitreal)
- Anti-C5 drugs
  - Anti-C5 aptamer (ARC1905) (intravitreal)
- Anti-C5 monoclonal antibodies:
  - LFG316 (intravitreal)
  - Eculizumab (intravenous)
- Anti-Factor D Fab
  - Lampalizumab (intravitreal)

Slide Courtesy of Philip J. Rosenfeld, MD, PHD

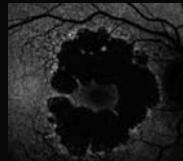
## Current Hypothesis for GA Pathophysiology

Oxidative stress      Genetic predisposition      Environment



Complement deposition between retinal pigment epithelium (RPE) and Bruch's membrane<sup>1</sup>  
 Loss of complement regulation<sup>2</sup>  
 Blood-retina barrier breakdown<sup>2</sup>

**Geographic atrophy**



1. AREDS Research Group. *Arch Ophthalmol* 2001;119:1417-36; 2. Ambati J, et al. *Nat Rev Immunol* 2013;13(6):438-51. GA, geographic atrophy. Regillo CD, presented at Angiogenesis, Exudation, and Degeneration 2015.

## Factor D is Required for the Activation of the Alternative Complement Pathway

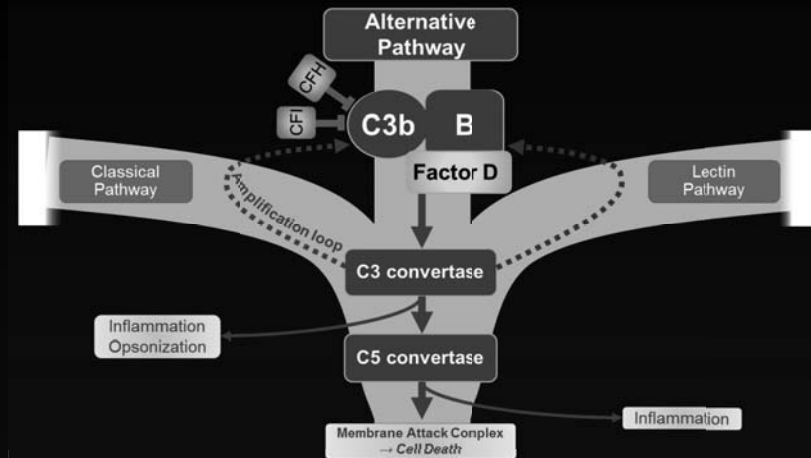


Figure based on the scientific information from the following sources: Owen J, Punt J and Stranford S. *Kuby Immunology* 7<sup>th</sup> edition, New York: W.H. Freeman and Co Ltd; 2013; Walport MJ, *N Engl J Med* 2001;344:1058-66. Regillo CD, presented at Angiogenesis, Exudation, and Degeneration 2015.

## Binding of Lampalizumab to Factor D Inhibits Activation of the Alternative Pathway Cascade

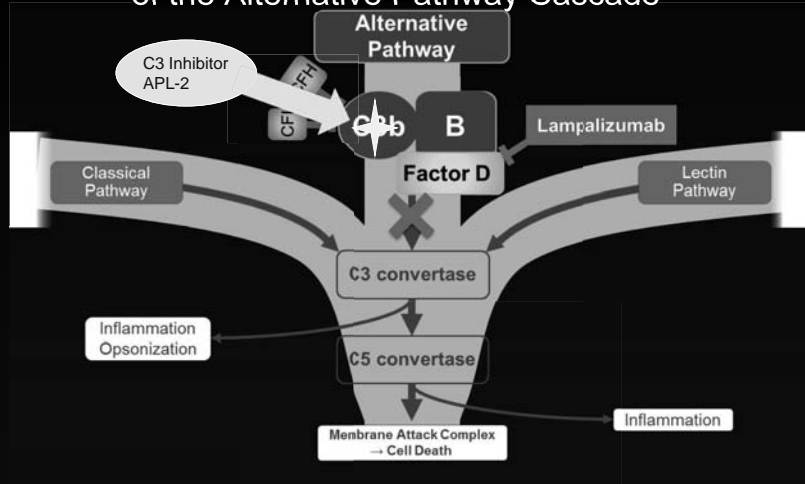


Figure based on the scientific information from the following sources: Owen J, Punt J and Stranford S. Kuby Immunology 7<sup>th</sup> edition, New York: W.H. Freeman and Co Ltd; 2013; Walport MJ, N Engl J Med 2001;344:1058-66. Regillo CD, presented at Angiogenesis, Exudation, and Degeneration 2015.

## Lampalizumab

- Failed to meet its Phase III clinical endpoint
- No longer being explored as a treatment

- The Lampalizumab Clinical Trial Program
- Designed to address an unmet need for >5 million GA patients globally

4 Studies | >2400 GA Patients | >275 Sites | >20 Countries

### Interventional

Chroma

Spectri

Two identically designed, randomized, Phase III, pivotal studies

### Observational

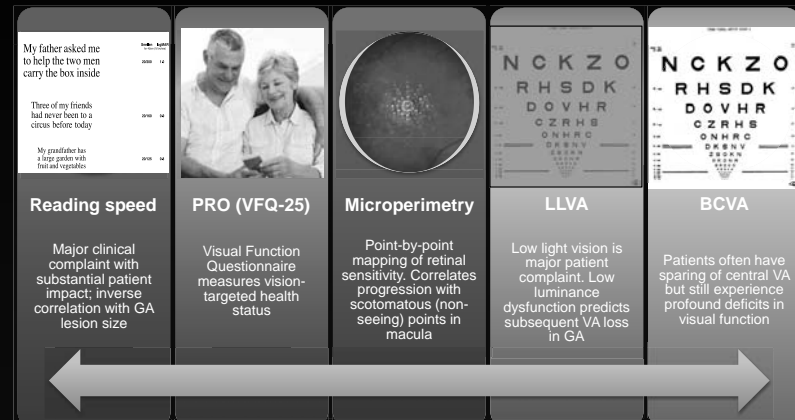
Proxima A

Proxima B

Two separate, parallel, prospective, observational studies

GA, geographic atrophy. Monés J, et al, presented at European Society of Retina Specialists Congress 2015.

## Visual Function Endpoints Phase III Secondary Efficacy Endpoints Will Evaluate Visual Function Outcomes Potentially More Relevant for GA Patient's Quality of Life



GA, geographic atrophy, LLVA, low luminance visual acuity; PRO, patient reported outcome. Regillo CD, presented at Angiogenesis, Exudation, and Degeneration 2015.

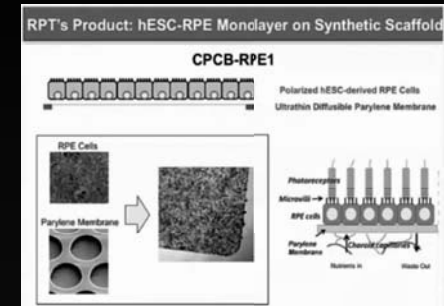
## Possible New Treatment for Dry AMD

### C3 Inhibitor APL-2

- Phase II study with 246 patients for 12 months
- 29% reduction in the rate of geographic atrophy through 12 months with monthly injections
  - Increase in development of wet AMD IF patients already had wet AD in the fellow eye
- Starting phase III in mid 2018

## Possible New Treatments to Reverse Dry AMD

- Reverse the damage from GA
  - Stem Cells
  - Gene Therapy

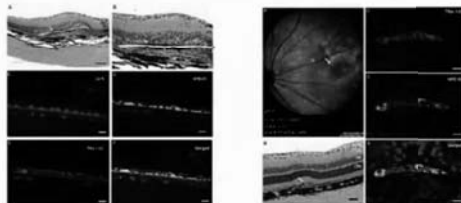


## Possible New Treatments for GA

### Subretinal Implantation of Retinal Pigment Epithelial Cells Derived From Human Embryonic Stem Cells: Improved Survival When Implanted as a Monolayer

Bruno Diniz,<sup>1,2</sup> Padmaja Thomas,<sup>1</sup> Biju Thomas,<sup>1,5</sup> Ramiro Ribeiro,<sup>1,2,4</sup> Yuntao Hu,<sup>1,5</sup> Rodrigo Brant,<sup>1,2</sup> Ashish Ahuja,<sup>1</sup> Darhong Zhu,<sup>1</sup> Laura Liu,<sup>1,6</sup> Michael Koss,<sup>1,7</sup> Mauricio Maia,<sup>2</sup> Gerald Chader,<sup>1</sup> David R. Hinton,<sup>1,3,8</sup> and Mark S. Humayun<sup>1,5</sup>

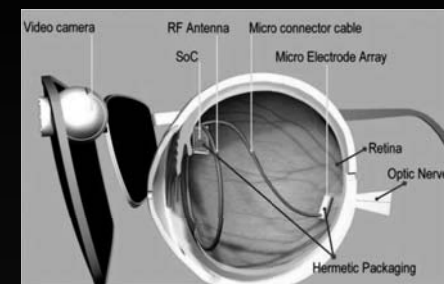
IOVS, 2013; 54:5087-5096




**CONCLUSIONS.** hESC-RPE can survive for at least 12 months in an immunocompromised animal model. Polarized monolayers of hESC-RPE show improved survival compared to cell suspensions. The lack of teratoma or any ectopic tissue formation in the implanted gels bodes well for similar results with respect to safety in human subjects.

## Artificial Retina: Retinal Prosthesis

- FDA approved
- Post-approval studies underway
- Regional centers of excellence
- \$100,000 per implant
- Limited indications
  - Retinal degenerations
  - Light perception vision or worse



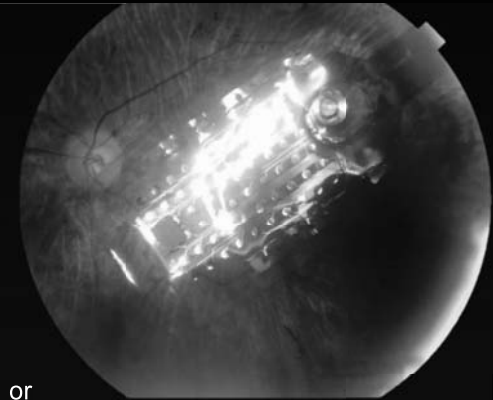
## How Does Retinal Prosthesis Work?



- Camera records real-time images
- Images are processed by a VPU (video processing unit)
- Signal is sent wirelessly to a coil implanted on the eye wall
- Coil is connected to an electrode array which lies on top of the retina; this must be implanted surgically in one eye
- Electrodes then stimulate remaining retinal cells

## Artificial Retina: Retinal Prosthesis

- FDA approved
- Post-approval studies underway
- Regional centers of excellence
- \$100,000 per implant
- Limited indications
  - Retinal degenerations
  - Light perception vision or worse



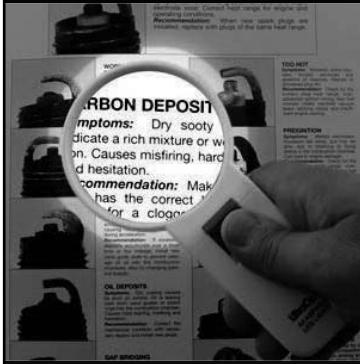## Outline

- Definitions
- Tools to assess and monitor intermediate to late disease
- Minimizing progression
- Current and emerging options for treatment
- Improving patient quality of life through vision loss aids and services

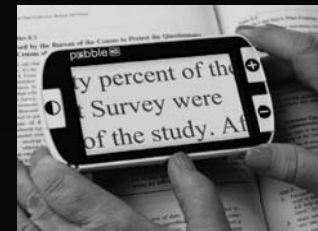
## Low Vision

- Low Vision Optometrists & Ophthalmologists
- Low Vision Technicians & Opticians
- Home Health (Occupational Therapists)
- Regional Centers of Excellence
  - Lighthouse
  - VA Medical Center “Boot Camp”

## Low Vision: Traditional Devices



## Low Vision: Innovations

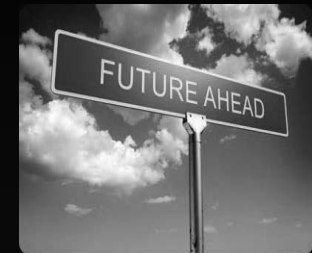

## Intraocular Telescope



## Conclusions

- Prevention is important
- Monitoring for disease activity is getting better and easier
- Wet AMD innovations may equal longer duration of action with synergistic therapies & new molecules
- Dry AMD with GA may finally have a treatment available to prevent progression
- Ultimate goal for GA will be to replenish damaged retina
- Low vision innovations help patients cope with deterioration in central vision



Thank you



Special Thanks

- Andrew Moshfeghi, MD, MBA
- Phil Rosenfeld, MD, PhD
- Carmen Puliafito, MD, MBA
- Nina, Berrocal, MD
- Harry Flynn, MD